Note: This copy is for your personal non-commercial use only. To order presentation-ready copies for distribution to your colleagues or clients, contact us at *www.rsna.org/rsnarights*.

Chronic Hypersensitivity Pneumonitis: CT Features—Comparison with Pathologic Evidence of Fibrosis and Survival[1]

Hakan Sahin, MD
Kevin K. Brown, MD
Douglas Curran-Everett, PhD
Valerie Hale, MD
Carlyne D. Cool, MD
Jason S. Vourlekis, MD
David A. Lynch, MD

Purpose: To retrospectively compare in patients with chronic hypersensitivity pneumonitis (HP) the computed tomographic (CT) imaging features suggestive of fibrosis with pathologic evidence of fibrosis at surgical lung biopsy and to compare a usual interstitial pneumonia (UIP) pattern at CT with survival.

Materials and Methods: Institutional review board approval and informed consent were obtained for this study, which was HIPAA compliant. Twenty-six patients (15 women, 11 men; age range, 37–76 years) with chronic HP had their surgical lung biopsy results reviewed by two pathologists for the presence of fibrosis. Two radiologists systematically reviewed the CT scans. The two radiologists were blinded to all clinical information, including pathologic diagnosis, patient information, and outcomes. The combination of a subpleural reticular pattern and lower zone predominance was considered a UIP pattern. CT findings were compared with the histopathologic presence of fibrosis, physiologic parameters, symptoms, and survival. The χ^2 or Fisher exact test (each two-tailed) was used to compare nominal and ordinal variables. A t test (with unequal variances) was used to compare continuous variables. The log-rank procedure was used to compare Kaplan-Meier survival curves.

Results: Fifteen patients had fibrotic HP at biopsy, and 11 had nonfibrotic HP. Patients with fibrotic HP had more extensive reticular pattern and were more likely to have traction bronchiectasis, honeycombing, and a UIP pattern than those with nonfibrotic HP ($P = .015$, $P = .007$, $P = .007$, respectively). Although the presence of histologic fibrosis was associated with decreased survival ($P = .003$), the CT features were not associated with decreased survival.

Conclusion: CT findings of extensive reticular pattern, traction bronchiectasis, and honeycombing are closely related to the presence of histologic fibrosis in chronic HP.

© RSNA, 2007

[1] From the Department of Radiology (H.S., V.H., D.A.L.), Department of Medicine (H.S., K.K.B., C.D.C.), and Division of Biostatistics (D.C.), National Jewish Medical and Research Center, 1400 Jackson St, Denver, CO 80206; Division of Pulmonary Sciences and Critical Care Medicine (K.K.B.), Departments of Preventive Medicine and Biometrics (D.C.), Physiology and Biophysics (D.C.), and Pathology (C.D.C.), University of Colorado at Denver and Health Sciences Center, Denver, Colo; and Department of Medicine, Inova Fairfax Hospital (Medical Critical Care Service), Falls Church, Va (J.S.V.). From the 2005 RSNA Annual Meeting. Received April 11, 2006; revision requested June 21; final revision received October 16; accepted November 3; final version accepted January 16, 2007. Supported by National Institutes of Health grant HL67671. **Address correspondence to** H.S. (e-mail: *sahinh@njc.org*).

© RSNA, 2007

Hypersensitivity pneumonitis (HP) is an environmental lung disease associated with inhalation of organic antigens or some chemicals (1). Histopathologically, it is represented by a pathologic triad of diffuse lymphoplasmocytic interstitial pneumonitis, cellular bronchiolitis, and poorly formed granulomas. The clinical manifestation of HP may be acute, subacute, or chronic (2), although the stages sometimes overlap both clinically and radiologically (3–7). The acute form of HP usually manifests after intense antigen exposure in a presensitized individual and usually clinically subsides after removal of the exposure. Persistent exposure may lead to chronic illness and may result in end-stage lung fibrosis, although only about 40% of patients with chronic HP have evidence of lung fibrosis (1,8–12).

Reported mortality rates range from 10%–21% in studies of patients with farmer lung (12–14), whereas chronic pigeon-breeder lung has demonstrated a 5-year mortality of 29% and a median survival of 11.2 years (15). In a recent study of patients with HP who have fibrosis at biopsy, the median survival time was 7.1 years (16). In regression analysis, only the presence of histopathologic honeycomb fibrosis (hazard ratio, 2.9) and the degree of fibrosis at surgical lung biopsy (hazard ratio, 2.2) increased the risk of mortality (16). The effect of lung fibrosis on survival appears to be independent of symptom duration, lung function, and antigen class (16). If computed tomography (CT) could be shown to be helpful in estimating survival, it could be used by the clinician to advise the patient about likely life expectancy and to plan treatment.

Advance in Knowledge

- Thin-section CT findings of reticular pattern, traction bronchiectasis, and honeycombing occur more frequently in patients who have fibrotic chronic hypersensitivity pneumonitis compared with patients who have nonfibrotic chronic hypersensitivity pneumonitis.

CT features in chronic HP have included irregular lines, traction bronchiectasis, lobar volume loss, and honeycombing (1,3,6,17–21). In some patients, the CT findings may mimic those of usual interstitial pneumonia (UIP) (20). Thus, the purpose of our study was to retrospectively compare in patients with chronic HP the features suggestive of fibrosis at CT with pathologic evidence of fibrosis at surgical lung biopsy and to compare the presence of a UIP pattern at CT with survival.

Materials and Methods

Study Patients and Clinical Evaluation

Patients had been previously enrolled in a prospective study having institutional review board approval that also included approval for future retrospective research with use of the study data. Patients provided informed consent for the prospective study and for future retrospective use of study data for research purposes. Both the prospective and retrospective studies were conducted in compliance with the Health Insurance Portability and Accountability Act (22). The database of the Interstitial Lung Disease Program at our institution includes more than 4000 patients who are registered and followed up prospectively. A review of this database for the period of 1982–2004 revealed 26 patients (15 women, 11 men; age range, 37–76 years at diagnosis) who had a clinical diagnosis of chronic HP, had undergone surgical lung biopsy, and had available CT scans. There were no fixed criteria for obtaining CT scans and biopsy specimens during this period. Availability of thin-section CT scans was a requirement for entry into the study. We chose not to impose a cut-off point for the time when thin-section CT became available at our institution and instead reviewed the records for all patients for whom CT scans were available. The earliest available CT scan was, in fact, obtained in 1987. The diagnosis of chronic HP required the presence of symptoms for more than 1 year.

Implications for Patient Care

- Identification of CT features of fibrotic hypersensitivity pneumonitis may indicate a poorer prognosis.
- Better understanding of prognosis may enable a more appropriate discussion with the patient about the management options.

The clinical record was reviewed (K.K.B.) to confirm clinical features consistent with the diagnosis. The "typical" clinical features referred to are the presence of symptomatic dyspnea or cough, sputum production, wheeze, crackles, clubbing, and the absence of an alternative diagnosis (eg, common variable immunodeficiency or infection) at follow-up that could account for the pathologic findings. Clinical history was abstracted from the medical record. The primary enrollment criterion was the identification of an HP pattern at surgical lung biopsy. Clinically relevant exposure to a specific antigen was not required. The clinical record was reviewed to confirm the absence of an alternative explanation for the pathologic findings.

The exposure history was defined as follows: The consulting physician obtained the environmental history at the initial evaluation. Exposures were classified into three categories: avian, microbial, and unknown. Antigen exposure was considered clinically relevant if the antigen was a known cause of HP and tempo-

Published online
10.1148/radiol.2442060640

Radiology 2007; 244:591–598

Abbreviations:
AV = alveolar volume
D_{LCO} = diffusing capacity of lung for carbon monoxide
HP = hypersensitivity pneumonitis
UIP = usual interstitial pneumonia

Author contributions: Guarantors of integrity of entire study, H.S., K.K.B., J.S.V., D.A.L.; study concepts/study design or data acquisition or data analysis/interpretation, all authors; manuscript drafting or manuscript revision for important intellectual content, all authors; manuscript final version approval, all authors; literature research, H.S., K.K.B., J.S.V., D.A.L.; clinical studies, H.S., K.K.B., V.H., C.D.C., J.S.V., D.A.L.; statistical analysis, H.S., D.C., D.A.L.; and manuscript editing, H.S., K.K.B., D.C., V.H., J.S.V., D.A.L.

Authors stated no financial relationship to disclose.

rally preceded the onset of symptoms. For home microbial contamination, we required independent confirmation of the exposure by means of either an industrial hygienist report or laboratory identification of the species with confirmatory serum precipitins. If the relevance of an antigen could not be established, the exposure was classified as unknown.

The date of surgical lung biopsy was accepted as the date of diagnosis. Survival period was calculated starting from the biopsy date and ending at either the last follow-up for the patients who were alive or lost to follow-up or the date the patient died. The mean interval (± standard deviation) between biopsy and CT was 1.3 years ± 1.7 (range, 0–5.4 years). Five CT examinations were performed before biopsy, and 21 were performed after biopsy. With regard to therapy, avoidance of the identified antigen and abatement procedures were recommended for all patients. Abatement procedures included removal of the primary antigen (if known) and extensive clean-up and/or renovation of the exposure site, including drapery and carpet removal and air duct cleaning. Medical therapy with corticosteroids was recommended in all patients. Corticosteroid doses ranged from 20 mg daily to up to 1 mg per kilogram of body weight for at least 6 weeks, depending on the severity of the disease. In patients who had a clinical response to corticosteroids, treatment was weaned to less than 15 mg daily by 3 months. In patients who did not respond to corticosteroids according to clinical measures (eg, symptoms, physiology, gas exchange, radiology), cytotoxic therapy (in the form of cyclophosphamide or azathioprine by means of a standardized treatment and monitoring protocol) was recommended. The patients with pathologic and imaging evidence of fibrosis more frequently underwent cytotoxic therapy when they did not respond to antigen avoidance (when known) and corticosteroids alone. The mean duration of follow-up was 5.7 years ± 4.7. The mean duration of follow-up after CT was 4.7 years ± 4.3. At the last follow-up, 16 patients were alive and 10 had died. Of the 10 deaths, two were due to progression of interstitial lung disease, one to sepsis, one to lung cancer, and one to surgery. The cause of death was unknown in the remaining patients.

Pulmonary Function Assessment

Pulmonary function testing was performed according to a standardized protocol (23,24). Thoracic gas volume and total lung capacity were determined with volume-displacement, pressure-compensated body plethysmography and compared with the expected values reported by Goldman and Becklake (25). Functional vital capacity and maximal expiratory flow rates were also determined with body plethysmography and compared with predicted values (26). The single-breath diffusing capacity of lung for carbon monoxide (DLCO) was measured by using the method of Blakemore and colleagues (27) and corrected for alveolar volume (AV) (DLCO/AV). The average of at least two determinations was calculated and compared with the predicted values of Crapo and Morris (28). When indicated, lung volumes, expiratory flow rates, DLCO, and DLCO/AV were corrected for race by using the scaling factors for African Americans put forward by Rossiter and Weil (29). The resting Pa_{O_2} was calculated by using the simplified alveolar air equation (30) on the basis of arterial blood gases measured with a blood gas analyzer (ABL-2; Radiometer, Copenhagen, Denmark).

Pathologic Assessment

The presence of clinical features of interstitial lung disease and an appropriate exposure history cannot provide a definitive diagnosis of HP. The addition of a specific imaging pattern or specific findings at bronchoscopy with transbronchial lung biopsy and bronchoalveolar lavage can occasionally provide a confident diagnosis. Although a confident diagnosis may be adequate in some patients, particularly for those with an easily removed antigenic exposure and a rapid and complete response to corticosteroids, a definitive diagnosis will usually require a surgical lung biopsy. A definitive diagnosis of HP was made in all of our patients.

Thoracoscopic biopsies were performed, with biopsy sites selected by the surgeon. CT was not specifically used to guide biopsies. Biopsy specimens were stained with hematoxylin-eosin. Two lung pathologists (C.D.C., with 10 years of experience, and another pathologist with 15 years of experience in lung pathology), who were blinded to all clinical information, independently reviewed the biopsy specimens. Disagreements were resolved with consensus. The pathologic features of a predominantly lymphoplasmocytic interstitial pneumonitis with bronchiolocentric accentuation and poorly formed septal granulomas served as the primary diagnostic criteria for inclusion. Interstitial fibrosis was defined as expansion of the alveolar septa due to mature collagen and involving more than 5% of the entire section of lung on the slide. In a previous article (31), interobserver agreement for this determination was 89% ($\kappa = 0.75$). However, we can find no information in the literature with regard to the reproducibility of the pathologic diagnosis of chronic HP at open lung biopsy.

CT Assessment

Two chest radiologists (D.A.L., with 20 years of experience, and V.H., with 15 years of experience in reading thin-section CT scans for interstitial lung disease) independently reviewed all CT scans for the presence or absence of features of fibrosis. All scans were obtained with GE 9800 or spiral scanners (GE Medical Systems, Milwaukee, Wis) by using thin-section collimation (1–1.5 mm) with a high-spatial-resolution reconstruction algorithm and scanning spacing of 10–40 mm. Expiratory images were obtained. Prone scans were obtained when dependent attenuation was present on supine images. The CT scans were scored according to a standard score sheet to identify the presence and extent of the findings. The following CT findings were graded on a scale of 0 to 4: reticular pattern, honeycombing, centrilobular nodules, ground-glass infiltration, emphysema, and mosaic attenuation. A score of 0 for any feature implied the absence of the feature, 1 indicated that the feature occupied less than 25% of the lungs by means of visual estimate, 2 indicated that the feature occupied 25%–50% of the lungs, 3 indicated that the feature occupied 50%–75% of the lungs, and 4 indi-

cated that the feature occupied more than 75% of the lungs. In addition, the presence or absence of traction bronchiectasis and lobar volume loss (assessed by means of fissural displacement) was recorded. Reticular pattern was classified as more than 25% and less than 25%, whereas the total extent of honeycombing, centrilobular nodules, ground-glass infiltration, emphysema, and mosaic attenuation was recorded on a scale of 0 to 8 as a combined score of both lungs.

The overall CT patterns were classified as HP (Fig 1), UIP (Fig 2), a mixture of HP and UIP, and other (not HP or UIP). The combination of centrilobular nodules, ground-glass infiltration, mosaic attenuation, and middle and/or upper

Figure 1

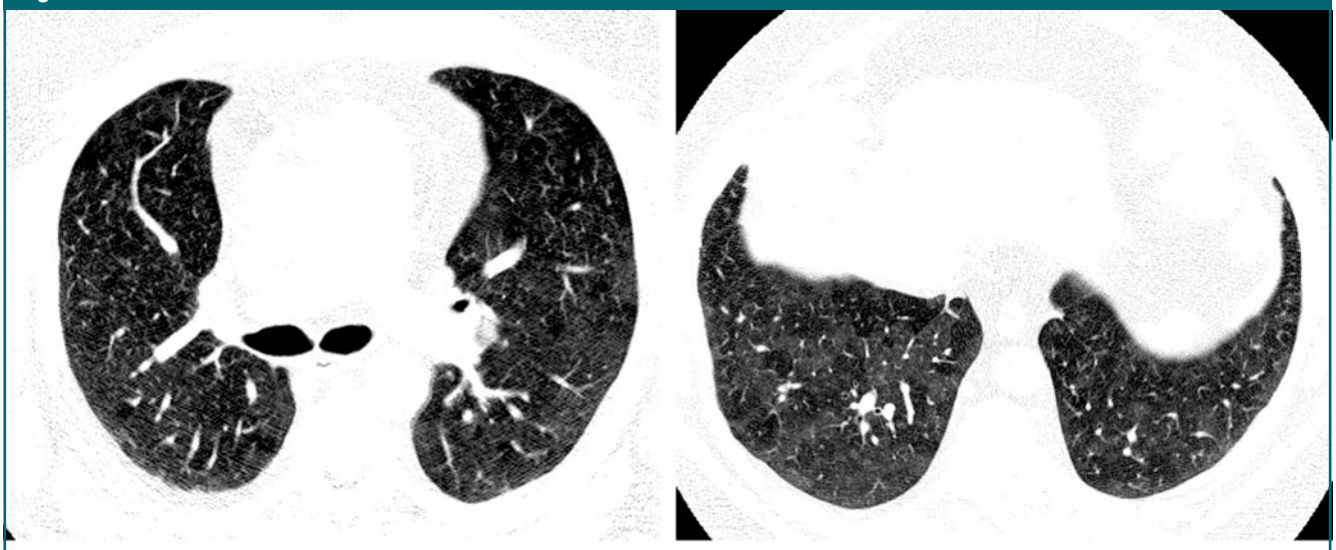

a. b.

Figure 1: Transverse thin-section CT scans in a patient with chronic HP with an HP pattern. **(a)** Scan obtained through midlungs shows ground-glass abnormality with mosaic attenuation. **(b)** Scan obtained through lower lungs shows ground-glass abnormality with mosaic attenuation.

Figure 2

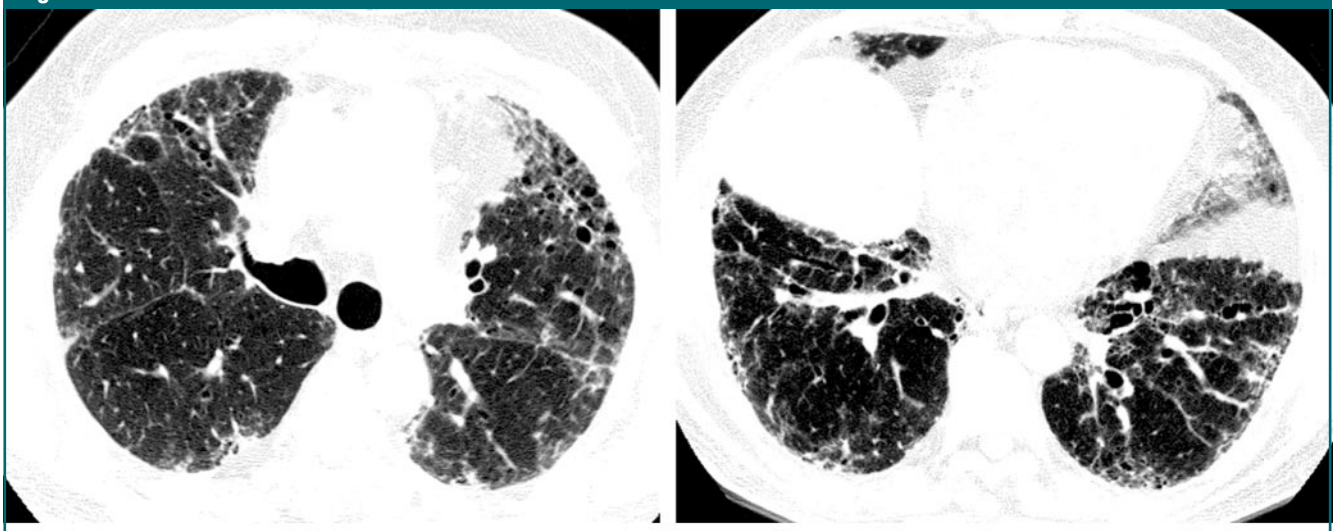

a. b.

Figure 2: Transverse thin-section CT scans in a patient with chronic HP and a UIP pattern. **(a)** Scan obtained through midlungs shows peripheral predominant reticular pattern and honeycombing. **(b)** Scan obtained through lower lungs shows basilar peripheral predominant reticular pattern, traction bronchiectasis, and honeycombing.

lobe distribution with or without fibrotic changes was considered to be typical HP. The combination of subpleural fibrotic changes, lower zone predominance, and minimal to no ground-glass infiltration was considered to be typical UIP. In our study, honeycombing was not required for a CT pattern of UIP. A CT pattern of combined features of HP and UIP was regarded as a mixture of HP and UIP. If a pattern did not clearly fit the criteria for either typical HP or UIP, it was considered to be indeterminate (not UIP, HP, or mixture of HP and UIP). From this classification, two groups were formed: those with a UIP pattern (including both pure UIP and mixed HP/UIP) and those without a UIP pattern. The radiologists were blinded to the results of histologic examination, and discrepancies in eight CT examinations were resolved by consensus.

Statistical Analysis

The χ^2 or Fisher exact (each two-tailed) was used to compare nominal and ordinal variables. A *t* test (with unequal variances) was used to compare continuous variables. The log-rank procedure was used to compare Kaplan-Meier survival curves; in this analysis of our study, patients who were lost to follow-up were right-censored. Statistical software (JMP IN, version 5.1.2; The Statistical Discovery Software, Cary, NC) was used for analyses. A *P* value of less than .05 was considered indicative of a statistically significant difference. All continuous variables were assessed for normality by using a combination of tests: Shapiro-Wilk, Kolmogorov-Smirnov, Cramer-Von Mises, and Anderson-Darling. All continuous data were consistent with having come from a normal distribution. By the date of the last follow-up, more than 50% of patients were alive. As a result, the median survival time cannot be estimated for certain subgroups. The statistical calculations were performed by authors (H.S., D.A.L., and D.C.).

The mean age and prevalence of symptoms and signs were calculated. The median symptom duration and pulmonary physiologic and gas exchange parameters were determined. The demographic features evaluated were age, sex, smoking status, and duration of symptoms. The symptoms and signs were dyspnea, cough, sputum, wheeze, crackles, and clubbing. The pulmonary physiologic parameters evaluated consisted of total lung capacity, functional residual capacity, residual volume, functional vital capacity, and forced expiratory volume in 1 second. The gas exchange parameters evaluated were DLCO, DLCO/AV, and resting Pa_{O_2}. Patients with histologic evidence of fibrotic HP were compared with those without histologic evidence of fibrotic HP with regard to demographic features, symptoms, signs, pulmonary physiologic parameters, and gas exchange parameters.

The prevalence of CT features of UIP pattern, honeycombing, lower lobe volume loss, traction bronchiectasis, and upper lobe volume loss were determined. The mean extent of CT features of reticular pattern, ground-glass attenuation, centrilobular nodules, emphysema, and mosaic attenuation were calculated. Patients with histologic evidence of fibrotic HP were compared with those without histologic evidence of fibrotic HP with regard to the extent and prevalence of CT features.

Median survival times were calculated and compared according to the presence or absence of fibrotic evidence at histologic examination, UIP pattern at CT, honeycombing at CT, traction bronchiectasis at CT, and more than 25% reticulation at CT. Specifically, the survival of patients with histologic evidence of fibrotic HP was compared with that of those without evidence of fibrotic HP. The survival of patients with a UIP pattern at CT was compared with that of patients without a UIP pattern, the survival of patients with honeycombing at CT was compared with that of patients without honeycombing, the survival of patients with traction bronchiectasis at CT was compared with that of patients without traction bronchiectasis, and the survival of patients with more than 25% reticular pattern at CT was compared with that of patients with less than 25% reticular pattern. The 5-year mortality and combined median survival rates were calculated.

The prevalence of antigen types was determined, and patients with histologic evidence of fibrotic HP were compared with those without histologic evidence of fibrotic HP with regard to exposure types. In addition, patients with evidence of fibrosis at CT were compared with those without evidence of fibrosis at CT with regard to exposure types.

Results

Pathologic Findings and CT Features

After the biopsy review, 15 of 26 patients (58%) were classified as having interstitial fibrosis; 11 patients (42%) did not have interstitial fibrosis. Six patients (23%) had a UIP pattern at CT (two with pure UIP and four with a mixture of UIP and HP features), and 20 (77%) did not have features of UIP (15 with features of HP and five with indeterminate patterns). All six patients with UIP at CT had fibrotic HP at histologic examination ($P = .02$).

The signs and symptoms in patients with fibrotic HP were similar to those in patients with nonfibrotic HP (Table 1); however, patients with fibrotic HP showed greater restrictive physiology and greater impairment in gas exchange. CT findings of honeycombing, traction bronchiectasis, and upper lobe volume loss were found only in those with fibrotic HP ($P = .007$, $P = .007$, $P = .999$, respectively) (Table 2). The extent of reticular pattern was significantly greater in patients with fibrotic HP than in those without fibrotic HP ($P = .02$).

The clinical characteristics of patients with a UIP pattern were similar to those of patients without a UIP pattern; however, patients with a UIP pattern showed evidence of greater restrictive physiology (lower functional residual capacity) and greater impairment in gas exchange (lower DLCO and DLCO/AV) (Table 3).

Patients with a UIP pattern had a lower extent of ground-glass attenuation ($P = .04$) and air trapping ($P = .02$) and were more likely to have honeycombing ($P = .001$), lower lobe volume loss ($P = .02$), traction bronchiectasis ($P = .005$), and reticular pattern ($P = .02$) compared with those without UIP. Histologic fibrosis was found in all six patients with a UIP pattern at CT and in nine of 20 patients (45%) without a UIP pattern. Minor hon-

Table 1

Comparison of Clinical and Physiologic Features in Patients with and in Patients without Histologic Fibrosis

Findings	Fibrotic HP (n = 15)	Nonfibrotic HP (n = 11)	P Value
Demographics			
Mean age (y)	65.8 ± 9.3	64.5 ± 11	.77
No. of women*	9 (60)	6 (54)	.99
No. of smokers*	11 (73)	5 (46)	.23
Symptoms			
Dyspnea*	15 (100)	11 (100)	NA†
Cough*	11 (73)	6 (54)	.42
Sputum*	6 (40)	5 (46)	.99
Wheeze*	7 (47)	7 (64)	.45
Median duration of symptoms (y)‡	5 (1–25)	3 (1–4)	.08
Signs			
Crackles*	13 (87)	6 (54)	.09
Clubbing*	4 (27)	1 (9)	.33
Pulmonary physiology			
Median total lung capacity§	73 (48–105)	97 (66–129)	.009
Median functional residual capacity§	68 (39–115)	89.5 (56–149)	.06
Median residual volume§	102 (28–189)	144 (76–256)	.06
Median forced vital capacity§	56 (34–89)	66.5 (44–95)	.33
Median forced expiratory volume in 1 second§	58 (40–89)	68 (33–91)	.87
Gas exchange			
Median D_{LCO}§	42 (25–84)	68 (49–118)	.008
Median D_{LCO}/AV§	72.5 (41–134)	101 (55–128)	.06
Median resting Pao_2 (mm Hg)‡	54 (44–73)	61.5 (57–75)	.02

* Data are given as numbers of patients. Numbers in parentheses are percentages.

† NA = not applicable; a P value could not be calculated because all patients had dyspnea.

‡ Numbers in parentheses are the range.

§ Numbers in parentheses are the range of the percentage predicted.

Table 2

Comparison of Extent and Prevalence of CT Findings in Patients with and in Patients without Histologic Fibrosis

CT Findings	Fibrotic HP (n = 15)	Nonfibrotic HP (n = 11)	P Value
UIP pattern*	6 (40)	0 (0)	.02
Honeycombing*	8 (53)	0 (0)	.007
Lower lobe volume loss*	7 (47)	3 (27)	.43
Traction bronchiectasis*	8 (53)	0 (0)	.007
Upper lobe volume loss*	1 (7)	0 (0)	.99
Reticular pattern with extent >25%*	11 (73)	2 (18)	.02
Ground-glass attenuation†	2.5 ± 1.7	2.8 ± 2.1	.69
Centrilobular nodules†	0.7 ± 0.9	0.9 ± 1.5	.73
Emphysema†	0.3 ± 0.6	0.6 ± 1.1	.34
Mosaic attenuation†	1.0 ± 0.9	1.1 ± 0.9	.84

* Data are number of patients. Numbers in parentheses are percentages.

† Data are means ± standard deviations.

eycombing was noted in two of the 20 patients without a UIP pattern at CT, but the distribution was not compatible with UIP.

Survival

The survival time in patients with fibrotic HP was shorter than that in patients with nonfibrotic HP (P = .001). There was no statistically significant difference in survival, however, between patients with a UIP pattern at CT and those without a UIP pattern (Fig 3).

Responsible Antigen

The environmental history helped identify the probable cause of HP in 17 patients (mold in seven, bird exposure in six, and miscellaneous other exposures in four); in the remaining seven patients, the antigen was not identified. There was no apparent relationship between the type of antigen exposure and the histologic or imaging patterns of HP.

Discussion

In our study, we found that fibrotic HP was associated with CT findings of reticular pattern, honeycombing, and traction bronchiectasis. The finding of a UIP pattern at CT occurred more often in patients with fibrotic HP than in those with nonfibrotic HP. Although the histologic pattern of fibrotic HP was associated with decreased survival, CT features were not associated with a survival difference.

The CT features of chronic HP have been well described (3,6,17,21,32) and include ground-glass attenuation, centrilobular micronodules, irregular reticular pattern, and traction bronchiectasis (3, 6). CT features suggestive of fibrosis may sometimes predominate in the midlung but can also show upper or lower lung predominance or diffuse distribution. The lung bases may be spared (17). Some of the CT features of chronic HP, particularly reticular pattern and honeycombing, overlap those of idiopathic pulmonary fibrosis and collagen vascular disease (20). It has been reported that 16% of all patients with HP (20) and 25%–40% of patients with chronic HP (6,17) may demonstrate a pattern indistinguishable from classic idiopathic pulmonary fibrosis and/

or UIP. The prevalence of honeycombing at CT in our study was 31%: In results of previous studies, this prevalence has ranged from 15% (3,20) to 69% (6). Zompatori et al (17) reported that CT signs of interstitial fibrosis were present in four of 12 patients with chronic HP diagnosed on the basis of bronchoalveolar lavage, history, and serum precipitins.

As with CT, chronic HP can show variable amounts of interstitial fibrosis at histopathologic examination. In our series, 58% of patients showed considerable fibrosis, whereas the remaining 42% did not. Foci of interstitial inflammation may be seen between areas of fibrosis. The interstitial inflammation is primarily lymphocytic but usually contains a larger number of plasma cells than is seen in acute and subacute HP. Alveolar walls may be thickened by alveolar cell hyperplasia. Constrictive bronchiolitis may be present (33,34). The classic poorly formed granulomas are seen in less than 50% of patients with chronic HP (35). Honeycombing and thickening of pulmonary arterioles are seen in the advanced stage of chronic HP (36).

It is usually thought that HP is associated with a low mortality (37). Previous investigations, however, have been largely limited to patients with acute HP (38). Vourlekis et al (16) demonstrated that, in patients with subacute or chronic HP, the 5-year mortality was 27% and the median survival was 12.8 years. The presence of histologic fibrosis has an effect on outcome, independent of any readily measurable clinical or physiologic variable. We did not evaluate the relationship between pulmonary function and survival in our study. Results of a previous study (16), however, showed no relationship between pulmonary function and survival in patients with chronic HP.

In our study, we found the median survival time in patients with fibrotic HP to be 3.9 years; the 5-year mortality rate was 61%. In the entire group of patients with chronic HP, the 5-year mortality rate was 30%. Similarly, in patients with chronic pigeon-breeder lung, Perez-Padilla et al (15) showed that the presence of histologic evidence of a UIP pattern is associated with a markedly shortened survival time. Their patients had an overall 5-year mortality rate of 29% and a median survival time of 11.2 years (15).

Our study had limitations. It includes a relatively small number of patients, and the number of patients with a UIP pattern at CT was small. It is a retrospective cohort study of patients from one large specialist center for the evaluation of interstitial lung disease, which may have led to selection of a higher proportion of patients with fibrosis. Selection bias may also have been introduced by the fact that criteria for obtaining CT scans and biopsy specimens in these patients were not prospectively delineated. Therefore, CT scans were not available for every patient with the diagnosis of chronic HP. The interval between biopsy and CT was relatively long, which potentially limits the comparability of the techniques. It is possible that a longer post-CT follow-up interval might have led to a substantial difference in survival times between patients with and patients without the UIP pat-

Table 3

Comparison of Clinical and Physiologic Features in Patients with and in Patients without the UIP Pattern at CT

Findings	UIP Pattern ($n = 6$)	No UIP Pattern ($n = 20$)	*P* Value
Demographics			
Mean age (y)	63.9 ± 12.7	65.6 ± 9.2	.77
No. of women*	4 (67)	11 (55)	.99
No. of current or former smokers*	4 (67)	12 (60)	.99
Symptoms			
Dyspnea*	6 (100)	20 (100)	NA†
Cough*	5 (83)	12 (60)	.38
Sputum*	3 (50)	8 (40)	.99
Wheeze*	1 (17)	13 (65)	.07
Median duration of symptoms (y)‡	1 (1–6)	3 (1–25)	.11
Signs			
Crackles*	5 (83.3)	14 (70)	.99
Clubbing*	1 (16.7)	4 (20)	.83
Pulmonary physiology			
Median total lung capacity§	60 (53–91)	85 (48–129)	.05
Median functional residual capacity§	58.5 (39–76)	85 (42–149)	.008
Median residual volume§	93.5 (28–174)	125 (71–256)	.21
Median forced vital capacity§	54 (39–89)	60 (34–95)	.76
Median forced expiratory volume in 1 second§	71 (43–89)	58 (33–91)	.59
Gas exchange			
DLCO§	29.5 (25–49)	63 (28–118)	.004
DLCO/AV§	68.5 (41–74)	82 (43–134)	.006
Resting Pao_2 (mm Hg)‡	54 (52–72)	61 (44–75)	.62

* Data are numbers of patients. Numbers in parentheses are percentages.

† NA = not applicable; the *P* value could not be calculated because all patients had dyspnea.

‡ Numbers in parentheses are ranges.

§ Numbers in parentheses are the range of the percentage predicted.

Figure 3

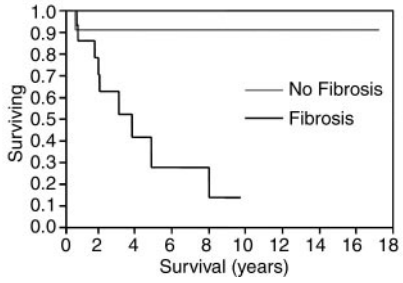

Figure 3: Graph shows survival curves for patients with and patients without fibrotic HP at histologic examination. Evidence of fibrosis at histologic examination in chronic HP is associated with decreased survival.

tern. The patterns of antigen exposure were heterogeneous. We conclude that CT findings of honeycombing, traction bronchiectasis, and reticular pattern occur more often in patients with evidence of fibrosis at pathologic evaluation.

References

1. Patel RA, Sellami D, Gotway MB, Golden JA, Webb WR. Hypersensitivity pneumonitis: patterns on high-resolution CT. J Comput Assist Tomogr 2000;24:965–970.
2. Ando M, Suga M, Kohrogi H. A new look at hypersensitivity pneumonitis. Curr Opin Pulm Med 1999;5:299–304.
3. Buschman DL, Gamsu G, Waldron JA Jr, Klein JS, King TE Jr. Chronic hypersensitivity pneumonitis: use of CT in diagnosis. AJR Am J Roentgenol 1992;159:957–960.
4. Glazer CS, Rose CS, Lynch DA. Clinical and radiologic manifestations of hypersensitivity pneumonitis. J Thorac Imaging 2002;17:261–272.
5. Hansell DM, Moskovic E. High resolution computed tomography in extrinsic allergic alveolitis. Clin Radiol 1991;43:8–12.
6. Adler BD, Padley SP, Muller NL, Remy-Jardin M, Remy J. Chronic hypersensitivity pneumonitis: high-resolution CT and radiographic features in 16 patients. Radiology 1992;185:91–95.
7. Hansell DM, Wells AU, Padley SP, Muller NL. Hypersensitivity pneumonitis: correlation of individual CT patterns with functional abnormalities. Radiology 1996;199:123–128.
8. Monkare S, Haahtela T. Farmer's lung: a 5-year follow-up of eighty-six patients. Clin Allergy 1987;17:143–151.
9. Bourke SJ, Banham SW, Carter R, Lynch P, Boyd G. Longitudinal course of extrinsic allergic alveolitis in pigeon breeders. Thorax 1989;44:415–418.
10. Lalancette M, Carrier G, Laviolette M, et al. Farmer's lung: long-term outcome and lack of predictive value of bronchoalveolar lavage fibrosing factors. Am Rev Respir Dis 1993;148:216–221.
11. Erkinjuntti-Pekkanen R, Rytkonen H, Kokkarinen JI, Tukiainen HO, Partanen K, Terho EO. Long-term risk of emphysema in patients with farmer's lung and matched control farmers. Am J Respir Crit Care Med 1998;158:662–665.
12. Emanuel DA, Wenzel FJ, Bowerman CI, Lawton BR. Farmer's lung: clinical, pathologic and immunologic study of twenty-four patients. Am J Med 1964;37:392–401.
13. Barbee RA, Callies Q, Dickie HA, Rankin J. The long-term prognosis in farmer's lung. Am Rev Respir Dis 1968;97:223–231.
14. Braun SR, doPico GA, Tsiatis A, Horvath E, Dickie HA, Rankin J. Farmer's lung disease: long-term clinical and physiologic outcome. Am Rev Respir Dis 1979;119:185–191.
15. Perez-Padilla R, Salas J, Chapela R, et al. Mortality in Mexican patients with chronic pigeon breeder's lung compared with those with usual interstitial pneumonia. Am Rev Respir Dis 1993;148:49–53.
16. Vourlekis JS, Schwarz MI, Cherniack RM, et al. The effect of pulmonary fibrosis on survival in patients with hypersensitivity pneumonitis. Am J Med 2004;116:662–668.
17. Zompatori M, Calabro E, Poletti V, Rabaiotti E, Piazza N, Viani S. Hypersensitivity pneumonitis: high resolution CT findings with pathological correlations—a pictorial essay. Radiol Med (Torino) 2003;106:44–50.
18. Akira M, Kita N, Higashihara T, Sakatani M, Kozuka T. Summer-type hypersensitivity pneumonitis: comparison of high-resolution CT and plain radiographic findings. AJR Am J Roentgenol 1992;158:1223–1228.
19. Grenier P, Chevret S, Beigelman C, Brauner MW, Chastang C, Valeyre D. Chronic diffuse infiltrative lung disease: determination of the diagnostic value of clinical data, chest radiography, and CT and Bayesian analysis. Radiology 1994;191:383–390.
20. Lynch DA, Newell JD, Logan PM, King TE Jr, Muller NL. Can CT distinguish hypersensitivity pneumonitis from idiopathic pulmonary fibrosis? AJR Am J Roentgenol 1995;165:807–811.
21. Remy-Jardin M, Remy J, Wallaert B, Muller NL. Subacute and chronic bird breeder hypersensitivity pneumonitis: sequential evaluation with CT and correlation with lung function tests and bronchoalveolar lavage. Radiology 1993;189:111–118.
22. Johnson MS, Gonzales MN, Bizila S. Responsible conduct of radiology research. V. The Health Insurance Portability and Accountability Act and research. Radiology 2005;237:757–764.
23. Watters LC, King TE, Schwarz MI, Waldron JA, Stanford RE, Cherniack RM. A clinical, radiographic, and physiologic scoring system for the longitudinal assessment of patients with idiopathic pulmonary fibrosis. Am Rev Respir Dis 1986;133:97–103.
24. Cherniack RM, Colby TV, Flint A, et al. Correlation of structure and function in idiopathic pulmonary fibrosis. Am J Respir Crit Care Med 1995;151:1180–1188.
25. Goldman HI, Becklake MR. Respiratory function tests: normal values at medium altitudes and the prediction of normal results. Am Rev Tuberc 1959;79:457–467.
26. Dubois AB, Botelho SY, Comroe JJ. A new method for measuring airway resistance in man using a body plethysmograph: values in normal subjects and in patients with respiratory disease. J Clin Invest 1956;35:327–335.
27. Blakemore WS, Forster RE, Morton JW, Ogilvie CM. A standardized breath holding technique for the clinical measurement of the diffusing capacity of the lung for carbon monoxide. J Clin Invest 1957;36:1–17.
28. Crapo RO, Morris AH. Standardized single breath normal values for carbon monoxide diffusing capacity. Am Rev Respir Dis 1981;123:185–189.
29. Rossiter CE, Weil H. Ethnic differences in lung function: evidence for proportional differences. Int J Epidemiol 1974;3:55–61.
30. Riley RL, Cournand A. Ideal alveolar air and the analysis of ventilation-perfusion relationships in the lungs. J Appl Physiol 1949;1:825–847.
31. Coleman A, Colby TV. Histologic diagnosis of extrinsic allergic alveolitis. Am J Surg Pathol 1988;12:514–518.
32. Silver SF, Muller NL, Miller RR, Lefcoe MS. Hypersensitivity pneumonitis: evaluation with CT. Radiology 1989;173:441–445.
33. Markopoulo KD, Cool CD, Elliot TL, et al. Obliterative bronchiolitis: varying presentations and clinicopathological correlation. Eur Respir J 2002;19:20–30.
34. Perez-Padilla R, Gaxiola M, Salas J, Mejia M, Ramos C, Selman M. Bronchiolitis in chronic pigeon breeder's disease: morphologic evidence of a spectrum of small airway lesions in hypersensitivity pneumonitis induced by avian antigens. Chest 1996;110:371–377.
35. Ando M, Arima K, Yoneda R, Tamura M. Japanese summer-type hypersensitivity pneumonitis: geographic distribution, home environment, and clinical characteristics of 621 cases. Am Rev Respir Dis 1991;144:765–769.
36. Seal RM, Hapke EJ, Thomas GO, Meek JC, Hayes M. The pathology of the acute and chronic stages of farmer's lung. Thorax 1968;23:469–489.
37. Schenker MB, Christiani D, Cormier Y, et al. Respiratory health hazards in agriculture. Am J Respir Crit Care Med 1998;158(suppl):S1–S76.
38. Kokkarinen J, Tukiainen H, Terho EO. Mortality due to farmer's lung in Finland. Chest 1994;106:509–512.